

Paravertebral O₂-O₃ Treatment in Mechanical Lumbar Pain in Riding Horses

A. VIGLIANI, E. BONIPERTI, E. SCUDO

Veterinary Surgeons

Key words: "back pain", O₂-O₃ therapy, paravertebral infiltration

SUMMARY – "Back pain" is common in horses, especially thoroughbreds and riding horses. Many soft tissue injuries and bone disorders are correlated with "back pain". Diagnosis is based on clinical examination possibly confirmed by x-ray and scintigraphy when available. Currently the most common treatments are local injection of steroids or systemic administration of steroids or NSAIDs. We studied 30 riding horses treated by local infiltration of O₂-O₃ administered in two sessions ten days apart. Despite our small cohort, the successful results show that O₂-O₃ therapy can be considered a valid alternative to current drug management protocols.

Introduction

"Back pain" is a common problem among riding horses in all equestrian disciplines, especially thoroughbreds and riding horses which most often present problems in the thoracolumbar spine (Jeffcott 1980).

Disorders correlated to "back pain" can be divided into two groups affecting either the soft tissues or associated with vertebral problems. Soft tissue injuries include muscle and ligament dilaceration, contractures, intervertebral disc disease and skin lesions in the saddle area. Vertebral disorders include ossifying deforming spondylosis, superimposed spinous processes, and arthrosis of the joint processes, neural arches and vertebral bodies. In particular, lesions to the spinous processes are displayed radiographically as a narrowing of the intervertebral space, erosion of the cranial and caudal margins and areas of sclerosis alternating with cyst-like radiolucencies.

Diagnosis is initially based on clinical examination gauging pain when applying paravertebral and interspinous pressure, and history-taking: attempts to avoid being ridden, loss of propulsive power and gait impairment. Instrumentally, diagnosis is confirmed by laterolateral radiograms and scintigraphy when available.

In case of lesions to the joint processes, neural arches or vertebral bodies, diagnosis must be confirmed radiologically using higher strength non portable devices and scintigraphy.

Current treatment for "back pain" is local injection of steroids or systemic administration of steroidal or non-steroidal anti-inflammatory drugs which may have major side effects and fail to ensure good medium and long-term outcome.

Materials and Methods

We undertook a two-year study on 30 horses (24 thoroughbreds, five trotting horses, one competition horse), in training and aged between three and 12 years (table 1).

The following parameters were chosen for assessment of back pain:

- thoracic pain and/or muscle contracture,
- pain between the spinous processes,
- lumbar pain and/or muscle contracture,
- change in spine curvature,
- asymmetric rump,
- pain in the sacro-iliac ligaments,
- gait impairment,
- loss of thrust/impulsion,
- "the horse lowers itself when the rider mounts".

Table 1

Number	Sex	Age	Height	Time	Symptoms										Treatment					
					Thoracic pain and contracture	Lumbar pain and contracture	Kyphosis	Rump asymmetry	Thoracic pain on interspinous pressure	Pain on pressure to the sacro-iliac ligaments	Gait impairment	Loss of thrust	Lowens when mounted	X-ray	Intraspinous infiltration	Paravertebral infiltration	Lombar infiltration			
1	C	3	G	To	+	+	-	-	-	-	-	-	+	-	-	-	+	-		
				T1	+	-	-	-	-	-	-	-	-	-	-	-	-	-	+	-
				T2	+	-	-	-	-	-	-	-	-	-	-	-	-	-	-	-
2	M	4	G	To	+	+	-	-	+	-	-	+	+	+	+	+	+	-		
				T1	-	-	-	-	-	-	-	-	-	-	-	-	-	-	+	-
				T2	-	-	-	-	-	-	-	-	-	-	-	-	-	-	-	-
3	F	3	G	To	+	+	-	-	+	-	-	+	-	-	-	-	+	-		
				T1	-	-	-	-	-	-	-	-	-	-	-	-	-	-	+	-
				T2	-	-	-	-	-	-	-	-	-	-	-	-	-	-	-	-
4	F	4	G	To	+	+	-	-	-	-	-	+	+	-	-	-	+	-		
				T1	+	-	-	-	-	-	-	-	-	-	-	-	-	-	+	-
				T2	-	-	-	-	-	-	-	-	-	-	-	-	-	-	-	-
5	M	3	G	To	+	+	-	-	-	-	-	+	+	-	-	-	+	-		
				T1	-	-	-	-	-	-	-	-	-	-	-	-	-	-	-	-
				T2	-	-	-	-	-	-	-	-	-	-	-	-	-	-	-	-
6	F	3	G	To	+	+	-	-	-	+	+	+	+	-	-	-	+	-		
				T1	+	+	-	-	-	+	-	+	-	-	-	-	-	-	+	-
				T2	-	+	-	-	-	+	-	-	-	-	-	-	-	-	-	-
7	F	3	G	To	+	+	-	+	-	-	+	+	+	-	-	-	+	-		
				T1	+	-	-	+	-	-	-	-	-	-	-	-	-	-	+	-
				T2	-	-	-	+	-	-	-	-	-	-	-	-	-	-	-	-
8	C	3	G	To	+	+	-	-	-	-	-	+	+	-	-	-	+	-		
				T1	+	-	-	-	-	-	-	-	-	-	-	-	-	-	+	-
				T2	-	-	-	-	-	-	-	-	-	-	-	-	-	-	-	-
9	C	5	T	To	-	-	-	-	-	+	+	+	-	-	-	-	+	+		
				T1	-	-	-	-	-	-	-	-	-	-	-	-	-	-	+	-
				T2	-	-	-	-	-	-	-	-	-	-	-	-	-	-	-	-
10	F	3	G	To	+	+	-	-	+	-	+	+	+	+	+	+	+	-		
				T1	+	-	-	-	-	-	-	-	-	-	-	-	-	-	+	-
				T2	+	-	-	-	-	-	-	-	-	-	-	-	-	-	-	-
11	C	6	G	To	+	+	-	-	+	+	-	+	+	-	+	+	-			
				T1	+	-	-	-	+	-	-	-	-	-	-	-	-	+	-	
				T2	-	-	-	-	-	-	-	-	-	-	-	-	-	-	-	-
12	C	3	G	To	+	+	-	-	-	-	-	+	+	-	-	+	-			

Table 1

Number	Sex	Age	Height	Time	Symptoms										Treatment		
					Thoracic pain and contracture	Lumbar pain and contracture	Kyphosis	Rump asymmetry	Thoracic pain on interspinous pressure	Pain on pressure to the sacro-iliac ligaments	Gait impairment	Loss of thrust	Lowers when mounted	X-ray	Intraspinous infiltration	Paravertebral infiltration	
				T1	+	-											+
				T2	+	-											-
13	F	3	G	To	+	+	-	-	+	-	+	+	+	-	-	+	-
				T1	-	+			-		-	-	-			+	-
				T2		+										+	-
14	M	2	G	To	+	-	-	-	-	-	+	+	-	+	-	+	-
				T1	-						-	-		-		-	-
				T2													-
15	F	3	G	To	+	+	-	-	-	-	-	+	-	-	-	+	-
				T1	+	-						+				+	-
				T2	+	-						+				-	-
16	F	3	G	To	-	+	-	-	-	-	-	+	+	-	-	+	-
				T1		-						-	-			+	-
				T2												-	-
17	F	3	G	To	+	+	-	-	+	-	+	+	+	+	+	+	-
				T1	+	+			+		+	+	+		-	+	-
				T2	+	+			+		+	+	+		-	-	-
18	M	3	G	To	-	+	-	-	-	-	-	+	+	-	-	+	-
				T1		+						+	-			+	-
				T2		-						-				-	-
19	C	3	G	To	+	-	-	-	-	-	-	+	+	-	-	+	-
				T1	+							-	-			+	-
				T2	-											-	-
20	C	12	G	To	+	+	-	-	-	-	+	+	-	-	-	+	-
				T1	+	-					-	-				+	-
				T2	+											-	-
21	C	12	C	To	+	+	+	-	+	+	+	+	-	-	-	+	+
				T1	-	-	+	-	-	+	-	-				+	-
				T2			+			+						-	-
22	F	3	G	To	+	+	+	-	-	-	-	+	-	-	-	+	-
				T1	-	+	+					+				+	-
				T2		-	+					+				-	-
23	C	3	G	To	+	+	-	-	-	+	+	+	-	+	+	+	-
				T1	-	-				+	-	-			-	+	-

follows table

Table 1

Number	Sex	Age	Height	Time	Symptoms										Treatment		
					Thoracic pain and contracture	Lumbar pain and contracture	Kyphosis	Rump asymmetry	Thoracic pain on interspinous pressure	Pain on pressure to the sacro-iliac ligaments	Gait impairment	Loss of thrust	Lowerers when mounted	X-ray	Intraspinous infiltration	Paravertebral infiltration	Lumbar infiltration
				T2													
24	M	8	T	To	+	+	-	-	-	-	-	+	-	-	-	+	-
				T1	-	-						-				+	
				T2												-	
25	M	8	G	To	+	+	-	-	-	-	+	+	+	-	-	+	-
				T1	-	-					-	-	-			+	
				T2												-	
26	M	4	G	To	+	+	-	-	+	-	-	+	+	+	+	+	-
				T1	+	-			-			-	-		-	+	
				T2	-											-	
27	M	4	G	To	+	+	-	-	-	-	-	+	+	-	-	+	-
				T1	+	+						-	-			+	
				T2	+	-										-	
28	M	3	T	To	+	+	+	-	-	+	-	+	-	-	-	+	+
				T1	-	-	+			-		-				+	-
				T2			+									-	
29	F	5	T	To	-	+	+	-	-	-	-	+	-	-	-	+	+
				T1		-	+					-				+	-
				T2			+									-	
30	M	9	T	To	-	+	-	-	-	-	-	+	-	-	-	+	
				T1		-						-				+	
				T2												-	

After clinical examination, in case of interspinous thoracic pain an x-ray was taken to disclose any changes along the edges of the spinous processes known as "kiss lesions", before proceeding to infiltration of the O₂-O₃ mixture in between the spinous processes. If pain was confined to the muscles we undertook paravertebral infiltration directly, whereas in case of suspicion or diagnosis of arthrosis in the lumbar facet joints, infiltration was carried out at a deeper periarticular paravertebral level.

An OZOLINE model E 80 device fitted with a differential digital photometer for real time display of O₂-O₃ concentrations was used for treatment.

Some of the horses were given mild sedation (10

mg detomidine) before treatment to make them easier to constrain and in most animals application of a twitch/barnacle was sufficient.

Two treatment sessions were held ten days apart followed by clinical follow-up ten days later. The time of clinical examination and the first infiltration was termed T0; the second infiltration was T1; clinical follow-up was T2.

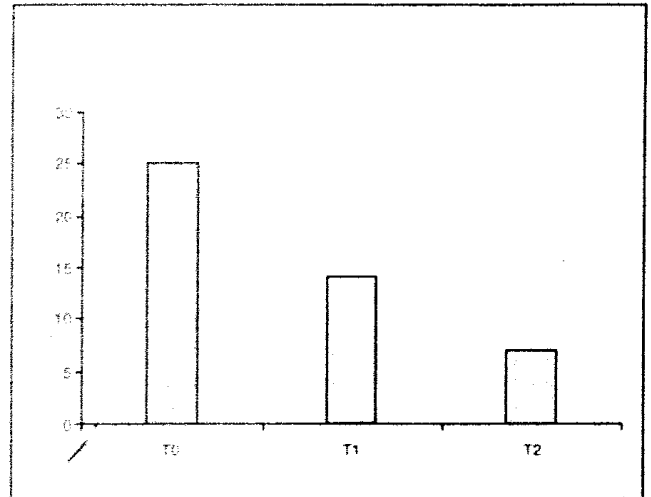
Paravertebral treatment consisted in administration of 15 ml of O₂-O₃ gas mixture at a concentration of 30 µg/ml with a 20 G needle 40 mm long, injected bilaterally into the muscle and about 4cm from the spinous apophysis throughout the area of pain.

Thoracic pain and contracture



Figure 1 Case n. 17. Narrowing of the spaces between the spinous processes of the 13th and 14th thoracic vertebrae with cysts at the cranial margin of the 14th thoracic vertebra.

T0	25
T1	14
T2	7



Graph 1

Lumbar pain and contracture


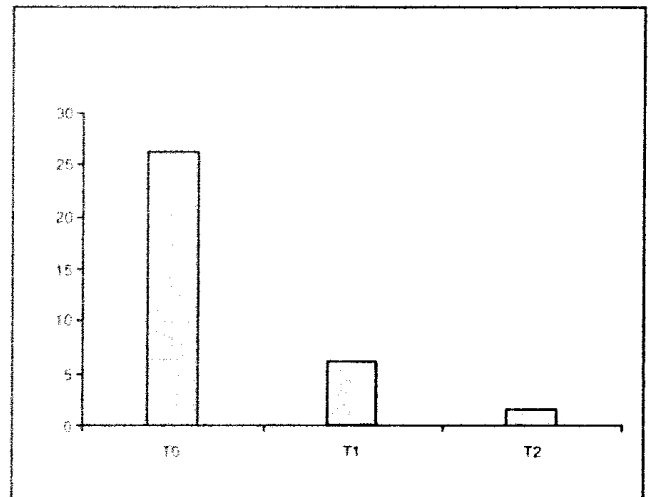


Figure 2 Case n. 26. Narrowing of the spaces between the spinous processes of the 15th and 16th thoracic vertebrae with cysts at the cranial and caudal margins of the 14th thoracic vertebra; sclerosis of the cranial margin of the 15th thoracic vertebra; narrowing of the space between the spinous processes of the 15th and 16th thoracic vertebrae.

T0	27
T1	6
T2	2



Graph 2

For interspinous disease we administered 15 ml of O.-O. gas mixture at a concentration of 30 µg/ml with a 20 G spinal needle 90 mm long injected in between the spinous processes. No anti-inflammatory drugs were given in the treatment period.

Results

Of the 30 horses examined, 25 presented thoracic pain and contracture but after the first treatment session 11 animals had a remission of symptoms, whereas only seven horses still had pain after the second infiltration (graph 1)

Thoracic interspinous pain was less common (eight horses) and after one treatment session two animals had a remission of symptoms.

Almost all the horses (27) had pain and contracture in the lumbar region. After the first infiltration only six animals still had pain and after the second session only two horses proved refractory to treatment (graph 2).

Four out of 30 horses also had a change in curvature of the lumbar spine and were treated by deep paravertebral infiltration into the facet joints. All four animals had a remission of pain after the first treatment session even though the spine curvature remained unchanged.

One horse with an symmetric rump failed to benefit from treatment whereas six animals also had pain in the sacro-iliac ligaments which resolved in three horses at T₁, but persisted in two so at T₂. Of the 11 horses presenting gait impairment, only one failed to improve after two infiltrations.

All horses examined had a loss of thrust/impulsion, but only ten out of 25 animals (24 thoroughbred and one competition horse) lowered themselves when their riders mounted the saddle.

All 30 horses examined received paravertebral

O₂-O₃ injection, six also had interspinous infiltration and five only periarticular infiltration.

Conclusion

Although our cohort is small, the O₂-O₃ treatment at interspinous and paravertebral level was well tolerated in back disorders in riding horses. These encouraging results show O₂-O₃ therapy can be considered a valid alternative to current drug management protocols.

References

- 1 Brina L, Villani PC: L'ecografia nel trattamento dell'ernia discale lombare con infiltrazioni in paravertebrale di ozono. *Rivista Italiana di Ossigeno-Ozonoterapia* 2: 147-152, 2003.
- 2 Dammrich K, Randelhoff A, Weber B: Morphological contribution to biomechanics of the equine thoracolumbar spine, and to pathogenesis of the "kissing spines" syndrome. *Pferdehilkunde* 9: 267-273, 276-281, 1993.
- 3 Erichsen C, Eksell P et Al: Relationship between scintigraphic and radiographic evaluations of spinous processes in the thoracolumbar spine in riding horses without clinical signs of back problems. *Equine Vet J* 36: 458-465, 2004.
- 4 Haussler KK, Stover SM, Willits NH: Pathologic changes in the lumbosacral vertebrae and pelvis in thoroughbred racehorses. *Am. J. vet. Res* 60: 143-153, 1999.
- 5 Hendrickson D: The thoracolumbar spine. In: *Adams' Lameness in Horses*, 5th edn., Ed: T. Stashak, Lippincott Williams & Wilkins, Baltimore 2002: 1053-1057.
- 6 Jeffcott LB: Pelvic lameness in the horse. *Eq. Pract* 4: 21, 1982.
- 7 Jeffcott LB: Disorders of the thoracolumbar spine of the horse. *Equine Vet J* 12: 197-210, 1980.
- 8 Moretti B, Lanzisera R et Al: Il trattamento con O₂-O₃ paravertebrale nelle lombalgie meccaniche. *Rivista Italiana di Ossigeno-Ozonoterapia* 2: 139-146, 2003.
- 9 Re L: Al Jaziri first UAE Pilot study on the therapeutic potential of oxygen-ozone mixtures. *Rivista Italiana di Ossigeno-Ozonoterapia* 2: 129-134, 2003.
- 10 Townsend HG, Leach DH et Al: Relationship between spinal biomechanics and pathological changes in the equine thoracolumbar spine. *Equine vet. J* 18: 107-112, 1986.
- 11 Walmsley JP, Pettersson H et Al: Impingement of the dorsal spinous processes in two hundred and fifteen horses: case selection, surgical technique and results. *Equine vet. J.* 34: 23-28 2002.

Dr.ssa Alessandra Vigliani
Via Elli Zoia 48
20153 Milan, Italy
+39 335 6849353
alessandra.vigliani@libero.it