

Total Clinical and Radiological Resolution of Acute, Massive Lumbar Disc Prolapse by Ozonucleolysis

The First Indian Case Report

V.S. KUMAR **

* *Department of Neurosurgery, Indraprastha Apollo Hospitals; New Delhi, India*

** *Kumar Pain Management and Specialty Centre; New Delhi, India*

Key words: lumbar discal hernia, oxygen-ozone treatment

SUMMARY – Direct injection of ozone (ozonucleolysis) has been proven to be a safe and effective alternative to open surgery for patients suffering from disc herniation in many centres around the world^{1,2,3,4,5}. From August 2003 to July 2004 45 patients with discogenic radiculopathy who had failed to respond to an average of twelve weeks of conservative treatment were treated by ozonucleolysis. Percutaneous injection of the disc(s) or foraminal injection of gas was performed in a prone position using a posterolateral approach in an out-patient setting. Over a three-week period, one injection of 4ml intradiscal ozone oxygen mixture at 29 mcg% conc. was followed by twice weekly injections of 10ml of O₃O₂ in the pararadicular region. 88% had a successful outcome (55% excellent, 33% good) and 12% were failures measured on the Odom scale.⁶ There was no ozone related morbidity and no patient had to be hospitalized for any complication related to the procedure. We present two case reports from India of patients with massive lumbar disc herniation treated by ozonucleolysis who made a full recovery.

Case Report 1

A 40-year-old male cook presented on 25/11/2003 with a work-related incapacitating low back and left leg pain with paresthesia and mild foot weakness of two-month duration. He had failed to respond to physical therapy, rest and analgesic and anti-inflammatory medications.

Straight leg raising was limited to 45 degrees with a moderate (3/5) weakness in left extensors of great toe and ankle and left L5 sensory loss. MRI scans (figure 1) showed a massive central protrusion, slightly more to the left, nearly occupying the entire canal. The patient refused surgical decompression and the option of ozonucleolysis was chosen after a detailed discussion.

Course

On 28/11/2003, ozonucleolysis (ozone discectomy) was performed using 4 ml intradiscal and 12 ml foraminal O₃O₂ mixture at a concentration of

29 mcg% under real time fluoroscopic navigation as recommended by Leonardi⁷. This was followed by twice weekly IM (pararadicular) O₃O₂ injections for three weeks.

There was a rapid resolution of symptoms. In two weeks the patient was asymptomatic. Straight leg raising was normal, motor strength in the left leg had returned to normal with recovery of sensory function.

A follow-up MRI scan (figure 2) on 17/04/2004 showed a near total resolution of the disc prolapse. He remained free of any complaints attributed to his back or leg and was without any neurological deficit.

On his last follow-up on 18/01/2005 he was working full time and remains fully asymptomatic.

Case Report 2

A 39-year-old woman presented on 1/11/2003 with an unyielding back and severe left leg pain during a golf swing of two weeks duration. She

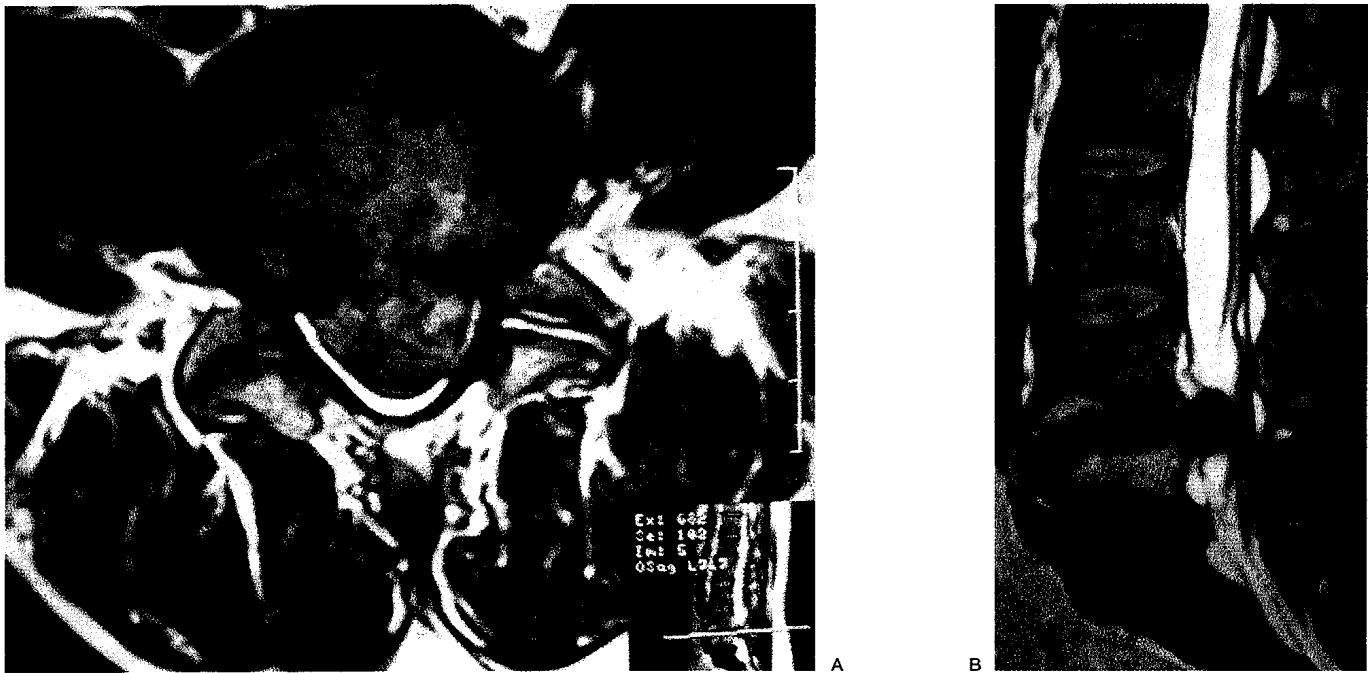


Figure 1 T2 weighted MRI image demonstrating a massive L4-5 disc prolapse nearly occupying the entire canal.

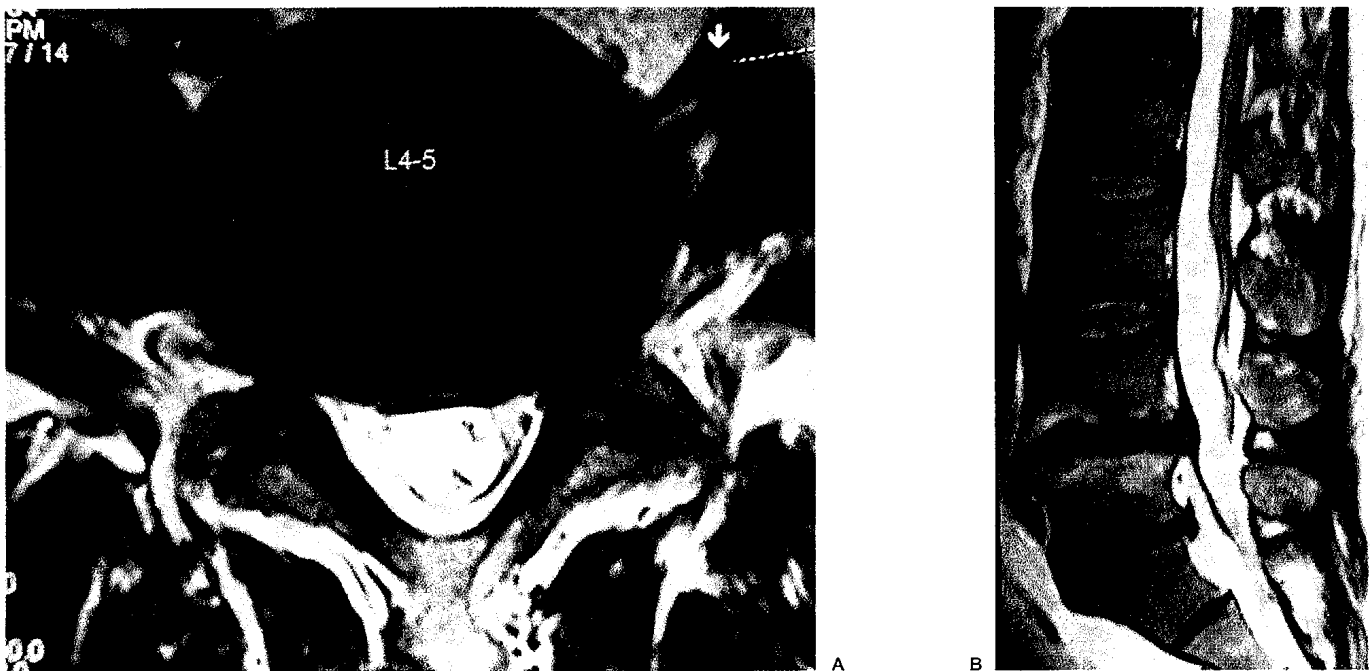
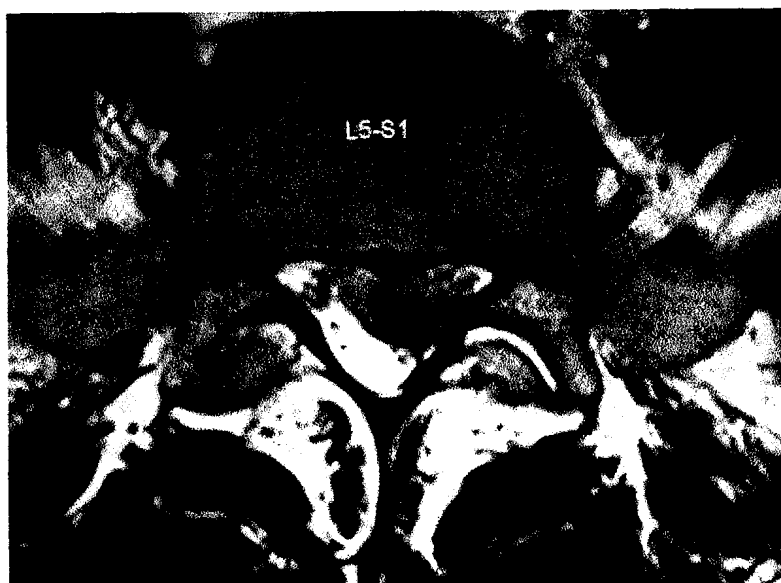

Figure 2 T2 weighted MRI image demonstrating near total resolution of disc prolapse.

had a history of back pain for which an epidural steroid injection had been given five months earlier with a successful outcome. On examination straight leg raising was limited to 30 degrees with absent left ankle reflex and S1 sensory loss. MRI scan (figure 3) showed a large left paracentral protrusion at left L5S1 level.

Course

On 6/11/2003, ozonucleolysis (ozone discectomy) was performed using 4 ml intradiscal and 12 ml foraminal O_3O_2 mixture at a concentration of 29 mcg% under real time fluoroscopic navigation. This was followed by twice weekly IM (pararadicular)

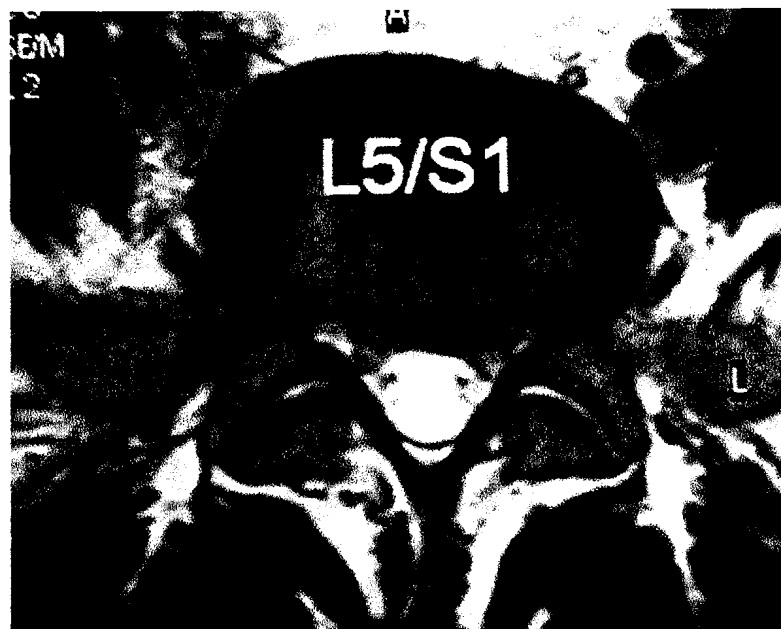

A

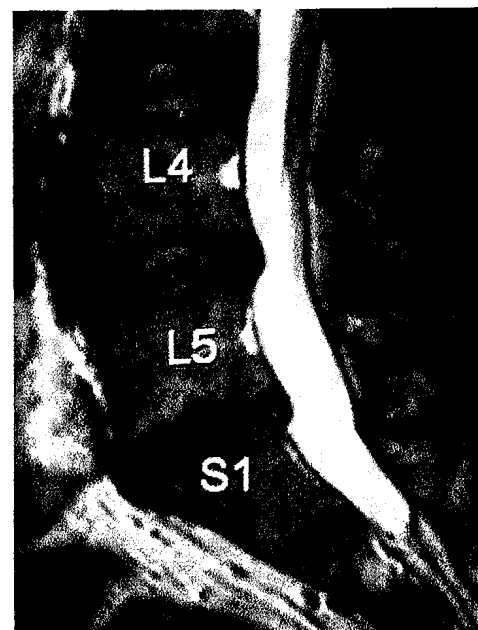
Figure 3 T2 weighted MRI image demonstrating a large left paracentral extrusion at L5S1 level.



B



A



B

Figure 4 T2 weighted MRI image demonstrating near total resolution of disc extrusion.

O₃O₂ injections and physical therapy for three weeks. She became asymptomatic in four weeks and resumed playing daily golf in three months. A follow up MRI scan (figure 4) shows total resolution of disc extrusion. On her last follow-up on 1/15/2005, she remained asymptomatic. She plays an 18 hole round of golf six days a week.

Discussion

Since disc prolapse was first observed by Dandy⁸ and subsequently described in detail by Mixter and Barr⁹ over 70 years ago, its treatment has confounded clinicians and investigators due a relatively high failure rate and complications associated with

the various treatment options^{10,11,12}. Outcome studies of lumbar disc surgery document a success rate between 49 and 90% and re-operation after lumbar discectomy ranging from 4% to 15%^{13,14,15,16,17,18}. Reasons for this failure have been variously attributed to several factors including dural fibrosis¹⁹, arachnoidal adhesions²⁰, muscle and fascial fibrosis and mechanical instability resulting from the partial removal of bony and ligamentous structures required for surgical exposure and decompression^{21,22,23,24,25}. There has been a surge of interest in finding alternative means of nerve root decompression while maintaining structural stability. Several refinements of root decompression have been developed including the use of magnification and introduction of various less invasive procedures like percutaneous automated discectomy, percutaneous laser discectomy, arthroscopic discectomy, and chymopapain chemonucleolysis, amongst others^{26,27,28}. Chemonucleolysis held an early promise with a success rate of about 80% that was nearly equal to that seen in the best surgical interventions^{29,30}. The procedure fell out of favor due to rare but severe complications of anaphylaxis from intradiscal chymopapain³¹. Injection of ozone for discogenic radiculopathy was developed in pursuit of finding safe and effective less invasive alternatives, free of the toxic effects seen with chymopapain^{2,3,32,33,34}.

In 1989, Verga injected ozone-oxygen mixture into the paraspinal region with a good outcome³⁴. Muto suggested intradiscal injection of ozone for disc hernia in 1998⁵. He injected ozone inside the disc under CT imaging. Leonardi popularized the use of fluoroscopic navigation with excellent results⁷.

Successful outcomes from ozone injection have been reported by practitioners from various European centres^{2,3,4,5,32}.

Striking in all these cases is the near absence of procedural complications. Over 30,000 cases of ozone injections performed without a serious complication establishes a formidable safety record for the procedure³⁴.

Our cases establish the efficacy of disc injection of ozone as a valid alternative to surgical decompression even in cases when a massive disc prolapse presents with radiculopathy without any clinical findings of cauda equina syndrome.

Acknowledgements

Funding for this research came from the M.L. Kumar Memorial Medical Trust.

The author would like to thank Rano Dayal and Anjali Kumar for assistance in preparing the material for this paper.

References

- 1 D'Erme M, Scarchilli A, Artale AM et Al: Ozone therapy in lumbar sciatic pain. *Radiol Med*: 95-21, 1998.
- 2 Muto M, Andreula C, Leonardi M: Treatment of herniated lumbar disc by intradiscal and intraforaminal oxygen-ozone (O₂-O₃) injection. *J Neuroradiol* 31: 183-9, 2004.
- 3 Valdenassi I, Nardelli G, Richelmi P et Al: *European Journal of Clinical Investigation* 33: 23-62-44, 2003.
- 4 Alexandre et Al: *Rivista Italiana di Ossigeno-Ozonoterapia* 1: 165-169, 2002.
- 5 Muto M, Avella F: Percutaneous treatment of herniated lumbar disc by intradiscal oxygen-ozone injection. *Interventional Neuroradiology* 4: 273-286, 1998.
- 6 Odom GL, Finney W, Woodhall B: Cervical disc lesions. *JAMA* 166: 23-28, 1958.
- 7 Leonardi M: Disc puncture under fluoroscopic guidance. *Rivista Italiana di Ossigeno-Ozonoterapia*: 1: 73-78, 2002.
- 8 Dandy WJ: Loose Cartilage from Intervertebral Disc Simulating Tumor of the Spinal Cord, *Arch Surg*, 19: 660-672, 1929.
- 9 Mixter WJ, Barr JS: Rupture of the intervertebral disc with involvement of the spinal canal. *N Engl J Med* 211: 210-5, 1934.
- 10 Morgan-Hough CVJ et Al: Primary and revision lumbar discectomy: A 16-year review from one center. *J Bone Surg* 2003: 85-B-871-4.
- 11 Ramirez LF, Thisted R: Complication and demographic characteristics of patients undergoing lumbar discectomy in community hospitals. *Neurosurgery* 25: 226-231, 1989.
- 12 Loupasis GA, Stamos K, Katonis PG et Al: Seven- to 20-Year Outcome of Lumbar Discectomy. *Spine* 24: 2313, 1999.
- 13 Junge A, Frochlich M, Ahrens S et Al: Predictors of bad and good outcome of lumbar spine surgery. A prospective clinical study with 2 years' follow up. *Spine* 21: 1056-1064, 1996.
- 14 Hirabayashi S, Kumano K, Ogawa Y et Al: Microdiscectomy and second operation for lumbar disc herniation. *Spine* 18: 2206-2211, 1993.
- 15 Hu RW, Jaglal S, Axcell Tet Al: Population-based study of reoperations after back surgery. *Spine* 22: 2265-2270, 1997.
- 16 Keskimaki I, Seitsalo S, Osterman H et Al: Reoperations after lumbar disc surgery: a population-based study of regional and interspecialty variations. *Spine* 25: 1500-1508, 2000.
- 17 Silvers HR, Lewis PJ, Asch HL et Al: Lumbar discectomy for recurrent disc herniation. *J Spinal Disord* 7: 408-419, 1994.
- 18 Weir BK, Jacops GA: Reoperation rate following lumbar discectomy. An analysis of 662 lumbar discectomies. *Spine* 5: 366-370, 1980.

- 19 Nygaard OP, Jacobsen EA, Solberg T et Al: Postoperative nerve root displacement and scar tissue. A prospective cohort study with contrast-enhanced MR imaging one year after microdiscectomy. *Acta Radiol* 40: 598-602, 1999.
- 20 Burton CV: Lumbosacral arachnoiditis. *Spine* 3: 24-30, 1978.
- 21 Nasca RJ: Lumbar spinal stenosis. Surgical considerations. *Journal of Southern Orthopaedic Association* 11: 127-134, 2002.
- 22 Hu SS et Al: Stenosis of the lumbar spine. In HB Skinner, ed., *Current Diagnosis and Treatment in Orthopedics*, 2nd ed. New York: McGraw-Hill 2000: 199-201.
- 23 Truumees E, Herkowitz HN: Lumbar spinal stenosis. Treatment options. *AAOS Instructional Course Lectures* 50: 153-61, 2001.
- 24 Casey PJ, Weinstein JN: Spinal stenosis. In S Ruddy et al., eds., *Kelley's Textbook of Rheumatology*. Philadelphia: W.B. Saunders 1: 516-517, 2001
- 25 Sengupta DK, Herkowitz HN: Lumbar spinal stenosis treatment strategies and indications for surgery. *Orthopedic Clinics of North America* 34: 281-295, 2003.
- 26 Onik G, Mooney V, Maroon J et Al: Automated percutaneous discectomy: a prospective multi-institutional study. *Neurosurgery* 26: 228-33, 1990.
- 27 Dabezies EJ, Langford K, Morris J et Al: Safety and efficacy of chymopapain (Discase) in the treatment of sciatica due to a herniated nucleus pulposus. Results of a randomized, double-blind study. *Spine* 13: 561, 1988.
- 28 Van Alphen HA, Braakman R, Bezemer PD et Al: Chemonucleolysis versus discectomy: a randomized multicenter trial. *J Neurosurg* 70: 869-875, 1988.
- 29 Weinstein J, Spratt KF, Lehmann T et Al: Lumbar disc herniation. A comparison of the results of chemonucleolysis and open discectomy after ten years. *J Bone Joint Surg* 68: 43-54, 1986.
- 30 Burkus JK, Alexander AH, Mitchell JB: Evaluation and treatment of chemonucleolysis failures. *Orthopedics* 11: 1677-1682, 1988.
- 31 Nordby EJ, Fraser RD, Javid MJ: Chemonucleolysis. *Spine* 21: 1102-5, 1996.
- 32 Andreula CF, Simonetti L, De Santis F et Al: Minimally invasive oxygen-ozone therapy for lumbar disk herniation. *American Journal of Neuroradiology* 24: 996-1000, 2003.
- 33 Torri G, Della GA, Casadei C: Clinical experience in the treatment of lumbar disk disease, with a cycle of lumbar muscle injection of an oxygen + ozone mixture. *Int J Med Biol Env* 27: 177-183, 1999.
- 34 Andreula CF: Personal communication, First Indo-Italian Lecture Series, Spine Intervention: Full Spectrum, New Delhi India 24 April 2004.

Vijay S. Kumar, M.D.
D 1/28 Vasant Vihar
New Delhi
110 057 India
Tel: +91 11 26142392 - 26154106
E-Mail: info@kpmc.com